

## CASE REPORT

### A VARIANT OF LAURENCE-MOON-BARDET-BIEDL SYNDROME SUPER-NUMERARY TEETH

Arun Kumar N<sup>1</sup>, Ramesh S.S<sup>2</sup>, Yashaswini L.S<sup>3</sup>, M.M. Basavaraju<sup>4</sup>, Mohan Kumar V<sup>5</sup>

#### HOW TO CITE THIS ARTICLE:

Kumar N.A., Ramesh S.S, Yashaswini L.S. "A Variant Of Laurence-Moon-Bardet-Biedl Syndrome Super-Numerary Teeth". Journal of Evolution of Medical and Dental Sciences 2014; Vol. 3, Issue 06, February 10; Page: 1369-1372, DOI: 10.14260/jemds/2014/1993

**ABSTRACT:** This family had a spectrum of many variants of Laurence moon bardet biedel syndrome in a single family, which had not been reported till date where the affected family members had supernumerary teeth. Hence we propose a new syndrome complex in this family which is similar to Bardet biedl syndrome, but with added features of supernumerary teeth.

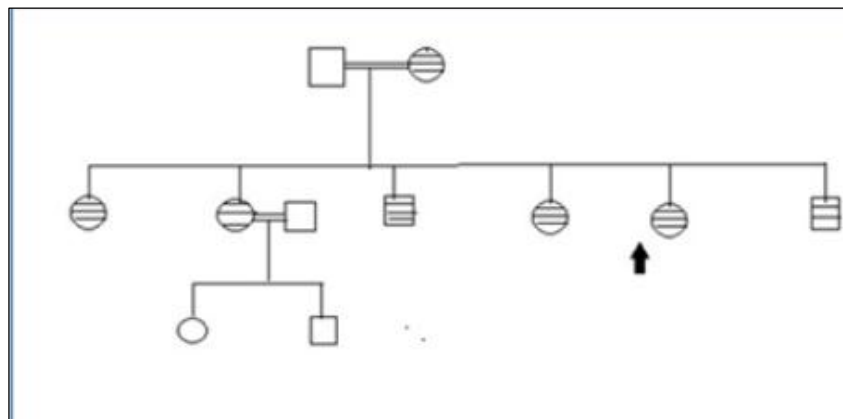
**KEYWORDS:** Laurence moon bardet biedel syndrome; supernumerary teeth.

**INTRODUCTION:** Laurence-Moon-Bardet-Biedl syndrome (LMBBS) is a rare, genetically heterogeneous, autosomal recessive disorder characterized by early onset retinitis pigmentosa, post axial polydactyly, central obesity, mental retardation, hypogonadism and kidney structural abnormalities or functional impairment. We report here a family with various syndromes of Laurence-Moon-Bardet-Biedl in a single family with affected family members having supernumerary teeth.

**CASE REPORT:** Here is a joint family of 11 members, which had 7 affected members with various sub syndromes of Laurence-Moon-Bardet-Biedl Syndrome; all the affected members had supernumerary teeth which was a rare feature in this variant of Laurence-Moon-Bardet-Biedl Syndrome.

Clinically all patients had obesity, mental retardation, hypogonadism, polydactyly, retinitis pigmentosa with an additional feature supernumerary teeth which was not seen in the unaffected family members.

#### Family history



## CASE REPORT

Patients	Supernumerary-teeth
A. (Biemond II variant)	Yes (3)
B. (WEISS VARIANT)	Yes(2)
C. LMBSS without obesity variant)	Yes(4)
D. (Alstrom variant)(no obesity, with conductive deafness)	Yes(4)
E. with Amyotrophic lateral sclerosis both UMN and LMN type	Yes(3)
Patients	Supernumerary-teeth

Other family members: All have normal teeth pattern and number.

**DISCUSSION:** Five overlapping but distinct syndromes had been described with ocular and/or auditory defects, mental retardation, genital hypoplasia, obesity, and digital anomaly.

Solis-Cohen and Weiss incorrectly connected the entity described by Laurence and Moon with the syndrome independently delineated by Bardet and Biedl. It is clear that the Bardet-Biedl syndrome is distinct from the Laurence-Moon syndrome. In 1934, Biemond described a related entity, the Biemond II syndrome, characterized by short stature, iris coloboma, mental retardation, polydactyly, obesity, and hypogenitalism.<sup>1</sup>

In 1932, Weiss had described an additional variant in this symptom complex. He discussed two sisters with obesity, mental deficiency, nerve deafness, and genital dystrophy, a variant in which deafness may be considered the equivalent of the retinal degeneration.<sup>2</sup>

Lurie and Levy described two deaf patients as having Bardet-Biedl syndrome without evidence of retinitis pigmentosa. These Patients seem to have Weiss' variant of this symptom complex.<sup>3</sup> Alstrom et al defined a syndrome combining tapetoretinal degeneration, obesity, diabetes mellitus, and neurogenous deafness. Mental retardation was not present, and the diagnostic evaluation of hypogenitalism was inconclusive. Preaxial polydactyly was found in an otherwise normal nephew of the proband.<sup>4</sup>

### Diagnostic criteria:

On the basis of a review of the literature & observations the following criteria is used for diagnosis of the Bardet-Biedl syndrome: Four of the five cardinal symptoms have to be present to qualify for this diagnosis, with the cardinal symptoms being tapetoretinal degeneration, mental retardation, obesity, polydactyly, and hypogenitalism.

Patient A had all features of Biemond II 2 variant except that the patient did not have an iris coloboma. But had additional features like Supernumerary teeth, mild conductive deafness and acanthosis nigricans, which was not reported till now.

Patient B had all features of Weiss variant 3, but as per the Weiss variant neurogenic deafness is a substitute of retinitis pigmentosa, but here our patient had both features of neurogenic deafness and retinitis pigmentosa, with short stature & supernumerary teeth as an additional feature. So this patient has a variant of Weiss syndrome.

Patient C had all features of bardet biedel1 syndrome but without obesity with an additional feature of conductive hearing loss and additional feature of Supernumerary teeth.

Patient D had a feature suggestive of Alstrom's variant 4, 5 but patient had no neurogenic deafness but had conductive deafness an additional feature of Supernumerary teeth and cataract.

## CASE REPORT

Patient E had Amyotrophic lateral sclerosis UMN and LMN variant with an additional feature of Supernumerary teeth. This has never been reported till date.

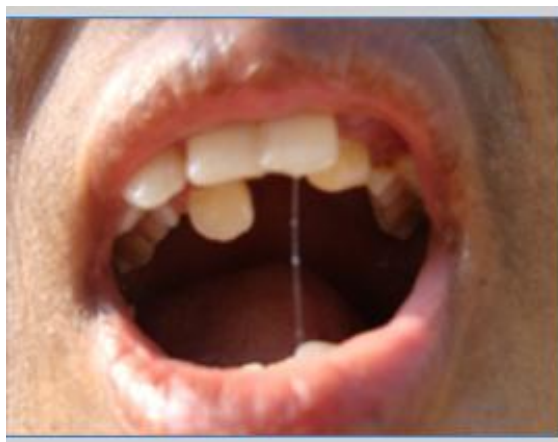Overall this family had a spectrum of many variants of Laurence moon bardet biedel syndrome in a single family, which has not been reported till date.

The present family had following features: Mental retardation, obesity, hypogenitalism, polydactyly, retinitis pigmentosa. Supernumerary teeth being an additional feature and was present in all the patients.

**CONCLUSION:** Hence we would like to propound a new syndrome complex in this family which is similar to Bardet biedl syndrome, but with added features of supernumerary teeth. Further molecular studies for confirming the exact mutation are needed. Clinically, they fall into a new syndrome complex.

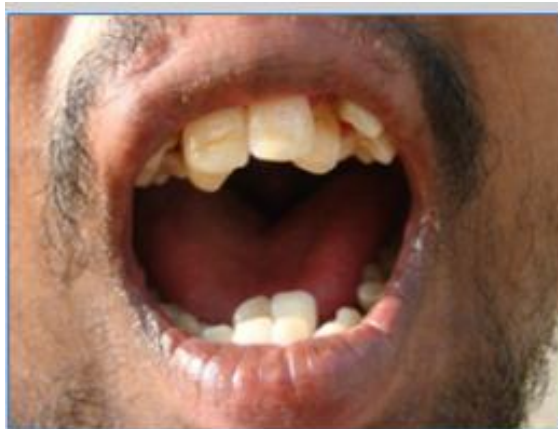### REFERENCES:

1. Laurence JZ, Moon RC: Four cases of retinitis pigmentosa occurring in the same family, and accompanied by general imperfections of development. Ophthalmol Rev 1866; 2:32-41.
2. Bardet G: Sur un syndrome d'obésité, de surdité, de nanisme avec polydactylie et retinite pigmentaire (contribution à l'étude des formes cliniques de l'obésité, de la surdité, de l'hypophysaire). Thèse Paris (Le Grand) 1920; 470:107.
3. Biemond A: Het syndrome van Laurence-Biedl en een nieuw aanverwant syndroom. Ned Tijdschr Geneesk 1934; 78:1801-1809.
4. Alstrom CH, Hallgren B, Nilsson LB, et al: Retinal degeneration combined with obesity, diabetes mellitus and neurogenous deafness: A specific syndrome (not hitherto described) distinct from the Laurence-Moon-Bardet-Biedl syndrome.
5. Weiss E: Cerebral adiposity with nerve deafness, mental deficiency and genital dystrophy: Variant of the Laurence-Biedl syndrome. Am J Med Sci 1932; 183:268-272.



**Fig. 1: Supernumerary teeth**

## CASE REPORT



**Fig. 2: Showing supernumerary teeth**

### **AUTHORS:**

1. Arun Kumar N,
2. Ramesh S.S,
3. Yashaswini L.S,
4. M.M. Basavaraju,
5. Mohan Kumar V

### **PARTICULARS OF CONTRIBUTORS:**

1. Senior Resident, Department of General Medicine, ESIC, Bangalore.
2. Assistant Professor, Department of General Medicine, Mysore Medical College & Research Institute.
3. Senior Resident, Department of General Medicine, RRMC, Bangalore.
4. Assistant Professor, Department of General Medicine, Mysore Medical College & Research Institute.

5. Consultant, Department of General Medicine, Vatsalya hospital, Mandya.

### **NAME ADDRESS EMAIL ID OF THE CORRESPONDING AUTHOR:**

Dr. Arun Kumar N,  
B-192, 10th Block, C.P.W.D. Quarters,  
Domlur, Bangalore – 560071.  
E-mail: dreamfullofcream@gmail.com

Date of Submission: 10/01/2014.

Date of Peer Review: 11/01/2014.

Date of Acceptance: 25/01/2014.

Date of Publishing: 04/02/2014.